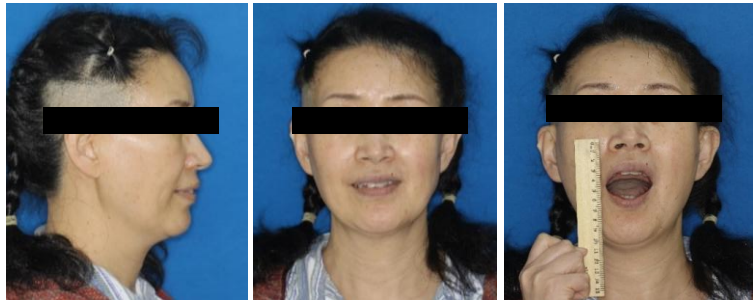


Endoscopically assisted fixation of a customized total TMJ prosthesis

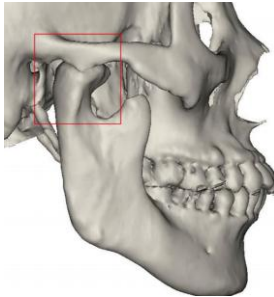
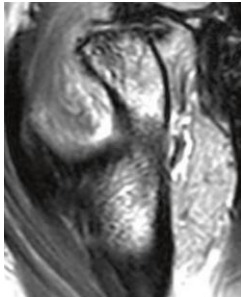
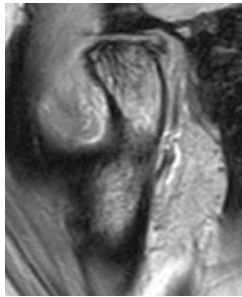
Preoperative



MRI-closed

MRI-open

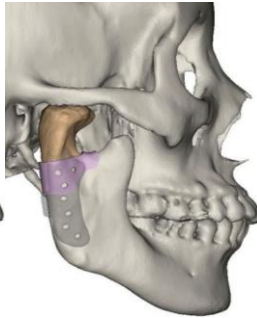
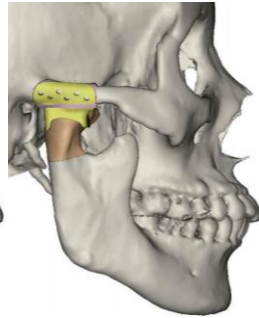
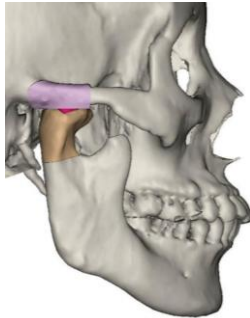
CT



Preoperative design based on CT

Articular fossa prosthesis

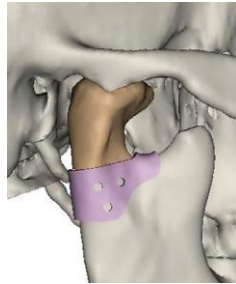
Subcondylar cutting guide



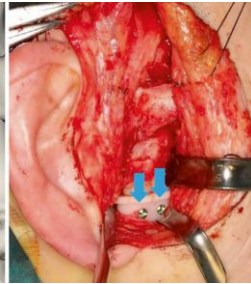
Prosthesis (yellow or black) screw holes and guide plate (pink) screw holes are in the same position.

Operation

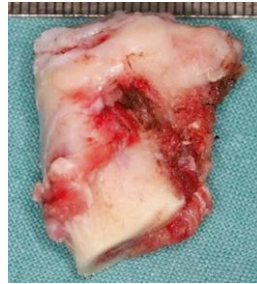① Operation based on design



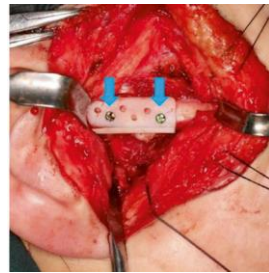
② Subcondylar osteotomy



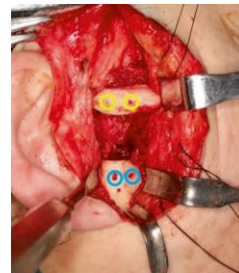Surgical specimen



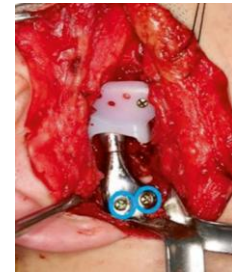③ Eminence osteotomy



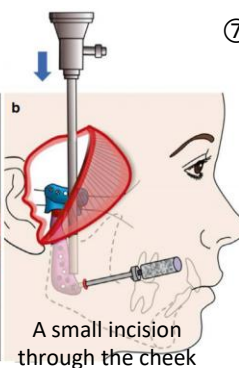
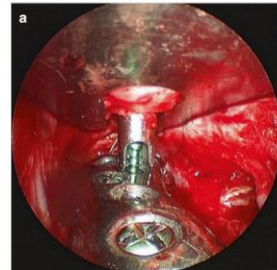
④ Screw holes after cutting



⑤ Prosthesis fixation based on the screws

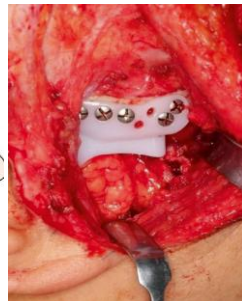


⑥ Endoscopically assisted fixation of the mandibular prosthesis



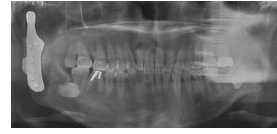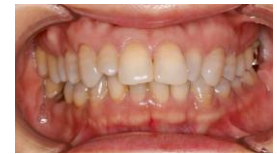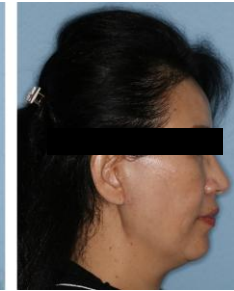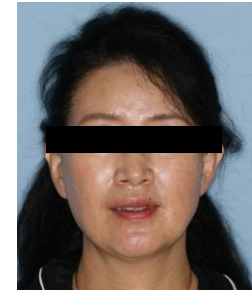
A small incision through the cheek

⑦ Subcutaneous fat graft to fill the space

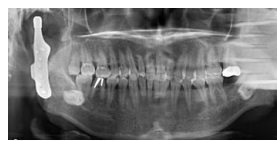
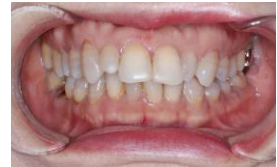
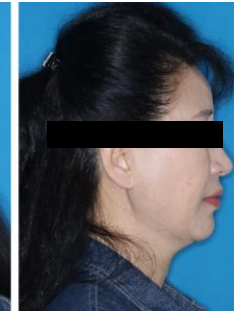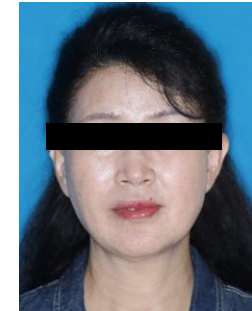Postoperative

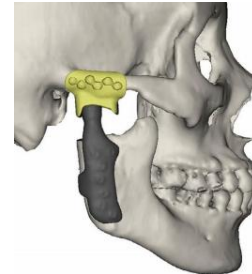
One year after surgery



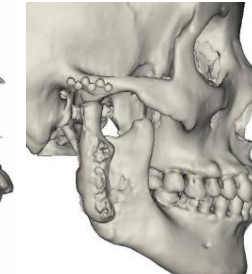
Three year after surgery



Immediate postoperative CT



One year postoperative CT



Three year postoperative CT

